



<https://doi.org/10.47811/bhj.99>

Angiofibrolipoma of the soft palate: a very rare cause of upper air way obstruction in an infant

Sonam Jamtsho¹

¹Department of ENT, Jigme Dorji Wangchuck National Referral Hospital, Thimphu, Bhutan

ABSTRACT

Introduction: Infants and children are very prone to air way obstruction due to smaller and immature air ways. There are multiple causes of upper airway obstruction in infants like infections, congenital lesions and rarely tumours of the upper airway. However, angiofibrolipoma, a rare variant of lipoma causing intermittent respiratory distress in an infant has not been reported until now.

Objective: To report a very rare case of angiofibrolipoma arising from the soft palate in an infant. **Case report:** Two and half months old female child reported to the department of otolaryngology with a history of intermittent airway obstruction since one month of age. After evaluation she was found to have a fleshy polypoidal mass above the laryngeal inlet arising from soft palate causing airway compromise. She underwent surgical excision with bipolar cautery under general anaesthesia. **Conclusions:** Few cases of angiofibrolipoma has been reported in adults but none has been reported in children. This is to report a case of angiofibrolipoma in child causing airway obstruction.

Keywords: Angiofibrolipoma; Lipoma; Infantile airway obstruction.

INTRODUCTION

Airway obstruction in an infant can be catastrophic and it is imperative that an experienced team is involved in the management at the very earliest. There are several causes of upper air way obstruction in an infant from congenital conditions like laryngomalacia, laryngeal web and well established benign tumours like hairy polyps. Angiofibroma causing upper airways obstruction is very rare that no cases have been reported in an infant so far.

Angiofibromas, a rare histopathological variant of lipoma is characterized by mature adipocytes, blood vessels and dense fibrous collagenous tissue. Lipomas are among the most common mesenchymal neoplasms, the head and neck regions are affected in 15% to 20% of cases and only 1% to 4% of these tumors are located in the oropharynx¹⁻³. The most affected anatomical sites in the oral cavity are the buccal mucosa, lips and tongue. The floor of the mouth, palate, retromolar pad and salivary glands are involved less frequently^{1,4}. They are usually seen in an adult after the age of 40 years and seldom reported in children and very rarely in an infant⁵⁻⁶. They can be sessile or pedunculated depending on the site of origin. When it involves mobile structures like soft palate and larynx, they tend to be

pedunculated as they are in constant motion during deglutition, respiration and phonation⁷⁻⁸. When it involves the air way, the severity of symptom depends upon the location and size of the tumour. The diagnosis of an angiofibrolipoma is a histological diagnosis and is the rarest variant of lipoma^{5,7,8}.

Literature search revealed a total of three cases of intraoral angiofibrolipomas (tonsil, buccal mucosa and retromolar region), one case in the larynx and ear canal each.

The following case is an angiofibrolipoma arising from the soft palate in an infant causing intermittent airway obstruction.

CASE PRESENTATION

A two and half months old female infant was seen by paediatrician due to intermittent respiratory distress since one month of age, which was relieved by turning the baby to prone position. Suspecting a case of laryngomalacia, she was referred to the department of otolaryngology for further evaluation. However, the mother gave a history of respiratory distress especially during breastfeeding which results in vomiting. On vomiting, respiratory distress settles and baby starts breathing normally. On two occasions she saw a grape sized lump in the baby's oral cavity. The baby also developed apnoeic spells at night which improved when she was kept in a left lateral position.

On admission to our department, baby weighed 5.2 kg and was breathing normally without any distress or stridor. The baby was afebrile and oral cavity examination revealed normal

Corresponding author:

Sonam Jamtsho
sonamj@jdwvnrh.gov.bt

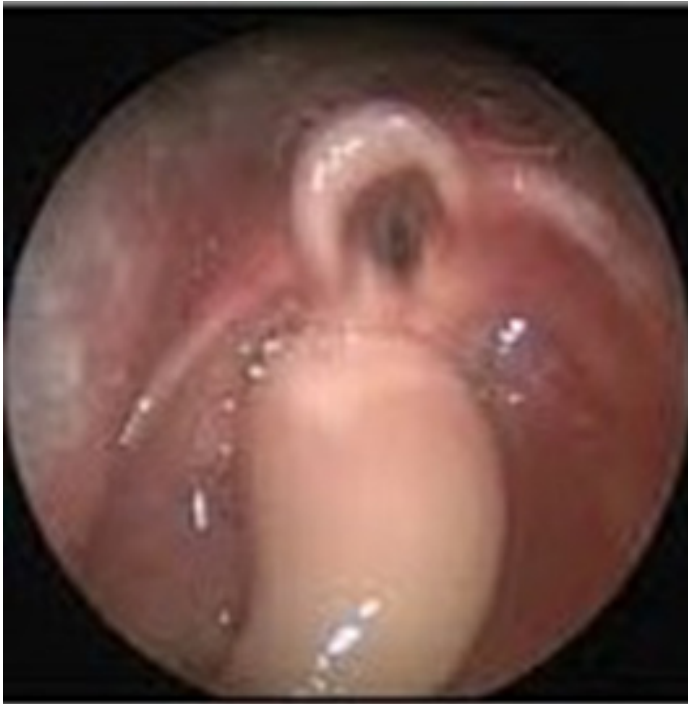

Figure 1. Endoscopic view of the angiofibrolipoma

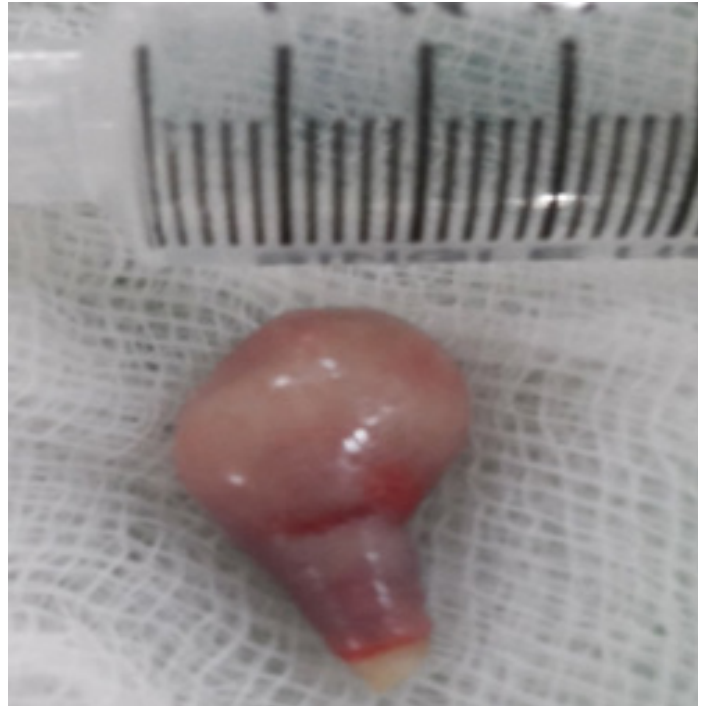

Figure 2. Angiofibrolipoma after excision

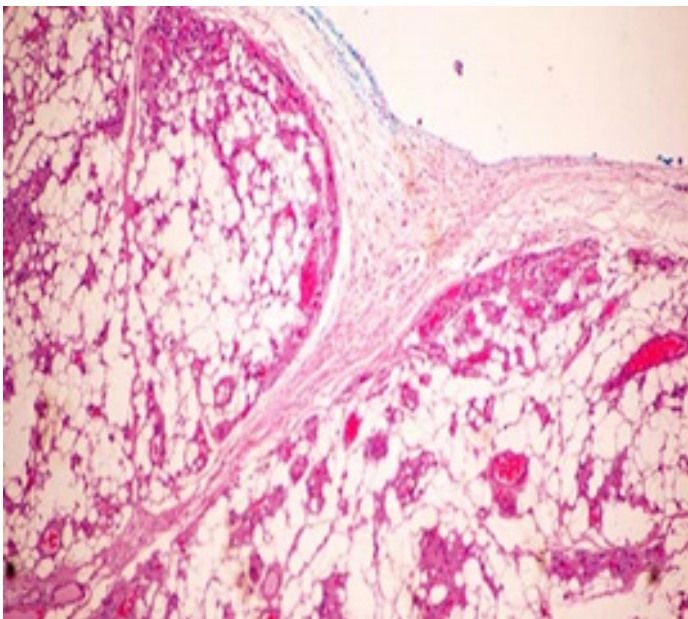


Figure 3. Histology of angio-fibrolipoma showing adipocytes with fibrous tissue and dilated lined by vessels

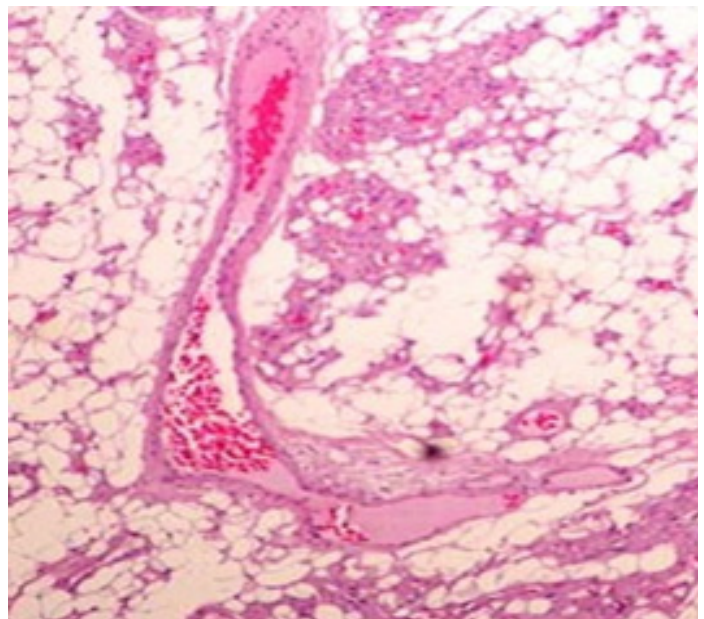


Figure 4. Angio fibrolipoma in this particular case squamous epithelium

findings. Chest examination showed bilateral vesicular breathing. She had normal heart sounds. No other congenital deformities were noted. Her cry was also normal.

Fibre optic nasopharyngolaryngoscopy was done via the right nostril and it revealed a fleshy, grape size pedunculated mass over the laryngeal inlet as shown in Figure 1. The site of origin could not be ascertained as the infant was crying. It was

assumed that the most likely origin of the mass must be from the vallecula. However, Epiglottis, vocal cords and hypopharynx were found normal. A diagnosis of pedunculated vallecular mass was made and excision under general anaesthesia was planned.

Complete blood count was normal and chest X-ray showed normal lung fields. 2-D echocardiogram was requested by anaesthetist to exclude any congenital heart conditions.

Since the infant was not cooperative, 2-D echocardiogram was performed under sedation, which was found to be normal. In the Echo room baby developed severe respiratory distress and cardiac arrest. Cardiopulmonary resuscitation was performed followed by intubation and baby was kept on ventilation. After obtaining a high risk consent from parents, she was taken for excision to the operation theatre.

During the surgery, no mass or any lesion was found in the oropharynx, larynx or hypopharynx. It was assumed that the mass underwent traumatic amputation during emergency intubation. Intra operative fiberoptic nasolaryngoscopy was done and the mass was found lying near the left choana in the nasopharynx. It was pushed to the oropharynx and delivered to the oral cavity. The fleshy tumour was found arising from the superior surface of the soft palate on its left side near the edge.

The mass was excised using bipolar cautery and sent for histopathological examination as shown in Figure 2. A prolonged slow recovery from anesthesia was done and was able to extubate as the baby had strong respiratory effort. The baby was kept in high dependency unit for 48 hours and then in the postoperative ward for 72 hours.

Histopathology revealed polypoid piece lined by squamous epithelium with underlying stroma composed of fibrous tissue with mature adipose tissue admixed with dilated vascular channels as shown in Figure 3 and 4. At six months follow up, the baby girl was active and growing well with no complaints of respiratory distress. Fiberoptic nasopharyngolaryngoscopy did not reveal any recurrent lesion.

DISCUSSION

Lipomas are called as universal tumour or ubiquitous tumour as it is the commonest tumour arising from the mesenchyme⁹. They mainly occur from the subcutaneous tissue in the neck, back, abdomen, armpit and face. Lipomas are rarely found in the oral cavity.

Lipoma constitutes about 0.5- 4.4% of all benign mesenchymal neoplasms of the oral cavity¹⁻³. The buccal mucosa is the most common site, followed by the tongue, floor of mouth, lips and gingiva¹⁻². Roux reported the first case of lipomas in the oral cavity in 1848 which was found in the alveolus termed as yellow Epulis¹⁰. Lipomas affecting the oral cavity are found in adults with the mean age of 50 years¹⁻³. It is very rarely reported in children.

Lipomas can be histologically classified into different types depending on the admixture of mesenchymal elements such as fibrolipomas, fibromyolipomas, osteolipoma, intramuscular lipoma, angioliipoma, salivary gland lipoma, spindle cell/pleomorphic lipoma, chondrolipoma or myxoid lipoma^{1,2,4,6,8}. Lipomas and fibrolipomas account for approximately 80% of all lipomas, followed by intramuscular lipomas and spindle cell lipomas^{1,2,12}. One of the rarest of the variants is angiofibrolipoma which was initially grouped under hamartoma¹¹. Kershisnik et

al in 1986, described the first case of angiofibrolipomas which contained fat cells, blood vessels, and connective tissue¹².

The Sign and symptoms of angiofibrolipomas will depend on the size and site of the lesion. In this case, it was a pedunculated mass about 2.5 cm in size with a fleshy stalk of about 5 cm. From clinical presentation and macroscopic appearance, the mass looked like hairy polyp but the histology proved it otherwise. Hairy polyps are rare but well established cause of neonatal and infantile air way obstruction¹³⁻¹⁵.

Since the respiratory distress started from the age of one, it could be a congenital lesion which grew big enough to obstruct the airway by two and half months time. However, it remains to be proven as there is no literature on congenital lipomas in oral cavity and palate because of its pedunculated nature, it fell down into the larynx when the baby was feeding and sleeping, thus causing respiratory distress. On turning the baby to prone position and during vomiting, the mass was pushed back to the oral cavity or nasopharynx thus opening the airway and relieving the distress. When the infant was turned towards the left lateral position on sleeping, the mass was lying in the valleculae or pyriform fossa thus not obstructing the laryngeal inlet.

During sedation of baby for the echocardiogram, the baby underwent deep sedation which caused the loss of pharyngeal muscle tone and the mass dropped down into the laryngeal inlet causing complete obstruction. Turning the baby to prone position couldn't relieve the obstruction because the muscle tone of the pharynx was lost or minimal due to sedation. Thus the baby underwent cardiac arrest due to hypoxia. Therefore in such cases where there is a pedunculated lesion causing intermittent airway obstruction like the case described here or in hairy polyps, any forms of sedation should be a contraindication as it can cause catastrophic airway obstruction leading to death.

The aetiology of lipomas remains elusive till date^{1-3,11,12}. Different theories of differentiation of multi-potent mesenchymal cells in fat tissue, cartilage and bone, to metaplasia of a pre-existing lipoma are described². The most widely acknowledged theory for the pathogenesis of lipoma is the "metaplastic theory" which postulates that lipomatous proliferation occurs due to the anomalous differentiation of in situ mesenchymal cells into lipoblasts, as adipose tissue can be derived from mutable connective tissue cells at more or less any topographic location in the body^{1,2,16}. Being the rarest of the variants of lipoma, angiofibrolipoma consist of mature adipocytes with fibrous tissue admixed with dilated vascular channels as shown in the Figures 3 and 4.

In literature there are few case reports of angiofibrolipomas being reported in the oral cavity and pharynx. A case of angiofibrolipoma of the buccal mucosa was in a 59 years old female by Brkic et al in 2010⁶. Another case of angiofibrolipoma involving the retromolar pad region was reported by Hosseini et al in 2014⁵. Bochnia et al. reported a case of pedunculated angiofibroma of the larynx causing dysphagia in a 68 year old man⁸. All the reported cases of angiofibrolipomas were

in the adult population. This is the first case of angiofibrolipoma being reported in an infant to the best of my knowledge.

Surgical excision is the treatment of choice for lipomas and pedunculated lesions are easy to excise¹⁻³. Recurrence after surgical excisions are very rare for oropharyngeal lipomas as compared to the deep lipomas which have a recurrence rate of 30% to 50%, probably because of the difficulty of complete surgical removal^{1,3,12}.

CONCLUSIONS

This paper reports an extremely rare case of angiofibrolipoma arising from the soft palate causing airway obstruction in a two and half month old infant. Literature review until now shows this is the first of such case to be reported.

REFERENCES

1. Naruse T, Yanamoto S, Yamada SI, Rokutanda S, Kawakita A, Takahashi H, et al. Lipomas of the oral cavity: clinicopathological and immunohistochemical study of 24 cases and review of the literature. *Indian Journal of Otolaryngology and Head & Neck Surgery*. 2015 Mar 1;67(1):67-73. [[Full Text](#) | [DOI](#)]
2. Furlong MA, Fanburg-Smith JC, Childers EL. Lipoma of the oral and maxillofacial region: Site and subclassification of 125 cases. *Oral Surgery, Oral Medicine, Oral Pathology, Oral Radiology, and Endodontology*. 2004 Oct 1;98(4):441-50. [[Full Text](#) | [DOI](#)]
3. Manor E, Sion-Vardy N, Joshua BZ, Bodner L. Oral lipoma: analysis of 58 new cases and review of the literature. *Annals of diagnostic pathology*. 2011 Aug 1;15(4):257-61. [[Full Text](#) | [DOI](#)]
4. Bakshi SS, Priya M, Coumare VN, Vijayasundaram S, Karanam L. A common tumor in an uncommon location: Lipoma of the palate. *Annals of maxillofacial surgery*. 2015 Jul;5(2):237. [[PubMed](#) | [Full Text](#) | [DOI](#)]
5. Agha-Hosseini F, Moslemi E. Angiofibrolipoma of the retromolar pad region. *The New York state dental journal*. 2014 Jun;33. [[Full Text](#)]
6. Brkic A, Özçamur Ç, Gürkan-Köseoglu B, Olgac V. Angiofibrolipoma of the buccal mucosa: a case report. *Journal of oral science*. 2010;52(1):173-6. [[Full Text](#) | [DOI](#)]
7. Bandéca MC, De Pádua JM, Nadalin MR, Ozório JE, Silva-Sousa YT, et al. Oral soft tissue lipomas: a case series. *Journal of the Canadian Dental Association*. 2007 Jun 1;73(5). [[Full Text](#)]
8. Bochnia M, Grabowski K, Zalewska A, Morawska-Kochman M. Angiofibrolipoma of the larynx: case report and literature review. *Head & neck*. 2016 Apr;38(4):E81-3. [[Full Text](#) | [DOI](#)]
9. Devi AN, Sowbhagya MB, Balaji P, Kumar TM. An uncommon case of fibrolipoma. *Indian Journal of Dental Research*. 2017 Nov 1;28(6):699. [[Full Text](#)]
10. Jacob LE, Babu SS, Nair SS, Koshy S. Angiofibrolipoma of the lower lip: a rare case report. *Journal of Indian Academy of Oral Medicine and Radiology*. 2018 Jul 1;30(3):318. [[Full Text](#) | [DOI](#)]
11. Saenz MA, Ortiz VJ, Jesús Jr M, González V, Andrade BG, Arce MA, et al. Dyspnea and dysphagia associated to hypopharyngeal fibrolipoma: a case report. *Annals of Medicine and Surgery*. 2017 Apr 1;16:30-3. [[Full Text](#) | [DOI](#)]
12. Linares MF. Intraoral lipomas: A clinicopathological study of 43 cases, including four cases of spindle cell/pleomorphic subtype. *Medicina oral, patologia oral y cirugía bucal*. 2019 May;24(3):e373. [[PubMed](#) | [Full Text](#) | [DOI](#)]
13. Gereige R, Ventura F, Giannoni E, Sandu K, Gorostidi F. Hairy polyp causing upper airway obstruction and respiratory distress in a newborn infant. *International Journal of Open Access Otolaryngology*. 2018 Mar 14;2(1):1-5. [[DOI](#)]
14. Tariq MU, Din NU, Bashir MR. Hairy polyp, a clinicopathologic study of four cases. *Head and neck pathology*. 2013 Sep 1;7(3):232-5. [[Full Text](#) | [DOI](#)]
15. Cheriathu JJ, Mohamed K, D'souza IE, Shamseldeen M. Autoamputation of congenital hairy polyp in neonate with stridor and respiratory failure. *WebmedCentral PAEDIATRICS* 2012;3(5):WMC003379. [[Full Text](#)]
16. Kaorey N, Mandale M, Bhavthankar J. Adipocytic tumors of orofacial region: Clinicopathologic appraisal of ten cases with a review of its variants. *Journal of Oral and Maxillofacial Pathology: JOMFP*. 2020 Feb;24(Suppl 1):S115. [[PubMed](#) | [Full Text](#) | [DOI](#)]