



<https://doi.org/10.47811/bhj.119>

Ocular sarcoidosis: a case report

Phuntsho Dorji¹

¹Department of Eye, Mongar Regional Referral Hospital, Mongar, Bhutan

ABSTRACT

Introduction: Sarcoidosis is a chronic granulomatous disorder which affects almost all parts of the body. It is usually idiopathic. Ocular involvement is noted in 25%–60% of patients with systemic sarcoidosis. It is very essential to rule out ocular tuberculosis as both can have similar presentations. **Case report:** A 26 year old patient presented with blurring of vision in left eye for nine months at Mongar regional referral hospital. Previously he was treated with topical steroids and cycloplegics for anterior uveitis. There were no systemic symptoms like dry cough, fever, chest pain and loss of weight. He had anterior chamber inflammation with iris nodule, vitritis and disc edema in left eye. The right eye had minimal anterior chamber reaction with only subtle iris nodule. Posterior segment examination was normal in right eye. He underwent blood investigations, chest X ray and contrast enhanced computed tomography of chest (CECT). The blood reports were normal. The chest X ray showed radiopaque lesions at both hilar region and multiple tiny radiopaque lesions in both lung fields. CECT chest showed significant paratracheal lymph nodes. Lymph node biopsy was not attempted due to extreme location. Based on clinical presentations and investigation findings a diagnosis of Presumed ocular sarcoidosis was made by using the criteria based on Revised International Workshop on Ocular Sarcoidosis. The patient was treated effectively with oral steroids for six months. Currently he is on low maintenance dose of oral steroids. **Conclusions:** Ocular sarcoidosis is a potentially blinding condition if not treated on time. There should be high suspicion of ocular sarcoidosis if patient presents with bilateral granulomatous anterior uveitis with hilar lymphadenopathy. However it is crucial to exclude ocular tuberculosis as both are mimickers of chronic granulomatous uveitis.

Keywords: Ocular sarcoidosis; International workshop on ocular sarcoidosis; uveitis.

INTRODUCTION

Sarcoidosis is a chronic granulomatous disorder which affects almost all parts of the body. The exact etiology is unknown. It is predominantly seen in certain ethnic and racial groups like African Americans. The 5 year age adjusted incidence of sarcoidosis was 35.5/100,000 in African Americans and 10.9/100,000 in Caucasians. Among African Americans the incidence is more in females (39.1/100,000) than males (29.8/100,000)¹. In our parts of world especially in India there is an estimated incidence of 62.1/100000 in one of the centre in New Delhi. Few reports showed male preponderance and other studies showed female preponderance from south India². Therefore the true burden of sarcoidosis is not known due to lack of epidemiological data.

There is no particular age at which sarcoidosis is typically seen. It can affect children as well as adults³. The most common organ involved are lungs, mediastinal lymph nodes, skin, and eyes. Ocular involvement is noted in 25%–60% of patients with systemic sarcoidosis. Ocular sarcoidosis usually manifest as uveitis (30%–70%) and conjunctival nodules (40%). Most of the sarcoid uveitis is bilateral and almost 90% of these are chronic. The diagnosis of ocular sarcoidosis is

quite challenging. The classical features of ocular sarcoidosis are large keratic precipitates (mutton fat Kps), low grade anterior chamber cells, tented peripheral anterior synechiae, posterior synechiae, nodules on iris and retrolental cells. The most common posterior segment features are vitritis with snow balls/snow banking, vasculitis of retinal vessels resembling candle wax dripping, diffuse sarcoid granuloma, retinitis and optic disc edema^{3,4,5,6}. Most of the ophthalmologist follow the revised International Workshop on Ocular Sarcoidosis (IWOS) criteria for diagnosis of ocular sarcoidosis^{4,5}. In IWOS there are four sub-groups of ocular sarcoidosis. They are: 1. Definite ocular sarcoidosis (biopsy proven with compatible uveitis). 2. Presumed ocular sarcoidosis (biopsy not done but chest X ray/CT chest showing bilateral hilar lymphadenopathy with compatible uveitis) 3. Probable ocular sarcoidosis (biopsy not done, chest X ray do not show any bilateral hilar lymphadenopathy but 3 clinical signs and 2 laboratory tests are positive) 4. Possible ocular sarcoidosis (lung biopsy done but report negative⁴, clinical signs present and 2 laboratory test positive)^{4,5}. The laboratory investigations helps in diagnosis but a tissue biopsy is a gold standard procedure for confirmation of disease⁷.

CASE REPORT

A 26 year old male presented with decreased vision in his left eye for past 9 months which was subacute in onset and gradually

Corresponding author:

Phuntsho Dorji
pdorji@mrrh.gov.bt

progressive. There was no pain or redness in eyes. He gave history suggestive of left sided facial weakness six months back which resolved spontaneously. There was no history of fever, rashes, joint pain, backache, recurrent oral ulcers, anorexia, weight loss, cough and shortness of breath. He had close contact with a person with pulmonary tuberculosis three years back. As per his past treatment record he was diagnosed as both eyes chronic granulomatous anterior uveitis. He was treated with topical steroids, cycloplegics and topical antibiotics. There was improvement in vision in right eye but left eye had persistent blurring of vision.

On examination, the best corrected visual acuity (BCVA) was 6/18 in left eye and 6/6 in right eye. The intraocular pressure (IOP) was normal. The lid and adnexa of both eyes were unremarkable. Slit lamp examination revealed moderate congestion with mutton fat keratic precipitates in both eyes. In right eye, there was 1+ cells in anterior chamber with busacca nodule at twelve clock hour and posterior synechiae at six clock hour. Lens was clear with normal vitreous and fundus with cup disc ratio of 0.3:1. In left eye there was cells 2+ with flare 1+ in anterior chamber with iris nodule and multiple posterior synechiae. The lens was cataractous (cortical cataract) which could be due to chronic inflammation. There was anterior hyaloid cells of 1+, moderate degree of vitritis, inferior exudates with snow balls. There was disc hyperemia and blurred disc margin. The posterior pole retina was apparently normal and peripheral retina could not be examined due to non-dilating pupil. Ultrasound B scan of left eye revealed moderate dot like hyper reflectivity in the vitreous cavity. The retina, choroid and optic nerve head were normal.

With these findings a diagnosis of right eye chronic anterior uveitis and left eye pan uveitis was made with a possible etiologies as tuberculosis, sarcoidosis or idiopathic. The report of complete blood count, liver function test, renal function test and random blood glucose were normal. However, the erythrocyte sedimentation rate (ESR) was only 8 mm/hr. Mantoux test was non-reactive with no induration even after seventy two hours. The viral markers were unremarkable and serum calcium was normal (9.6 mg/dl). The chest X-ray showed bilateral hilar shadows with military opacities in both lung field. CECT chest revealed scattered bilateral miliary pulmonary nodules predominantly in upper lobes with mediastinal lymphadenopathy, largest nodule measuring 1.6cm in right paratracheal region. The ultrasound of abdomen was normal.

With these clinical presentations, blood investigations, chest X ray and CECT, a diagnosis of presumed ocular sarcoidosis was made. The opinion on possibility of right paratracheal lymph node biopsy was sought from interventional radiologist. Due to extreme location of lymph node with associated risk of complications, biopsy was not attempted. The patient was started on high dose oral steroids 50 mg once a day for 2 weeks with tapering dose every 2 weekly by 10 mg. Other medications included proton pump inhibitor, calcium, topical

steroids and cycloplegics. The BCVA of left eye improved from 6/18 to 6/9 with resolution of anterior chamber inflammation, iris nodule, vitritis and disc edema.

Currently the patient is on low dose oral steroids 2.5 mg every alternate day.




Figure 1. Cluster of iris nodule in right eye (black arrow), subtle iris nodule (yellow arrow) with posterior synechiae (black arrow) in left eye

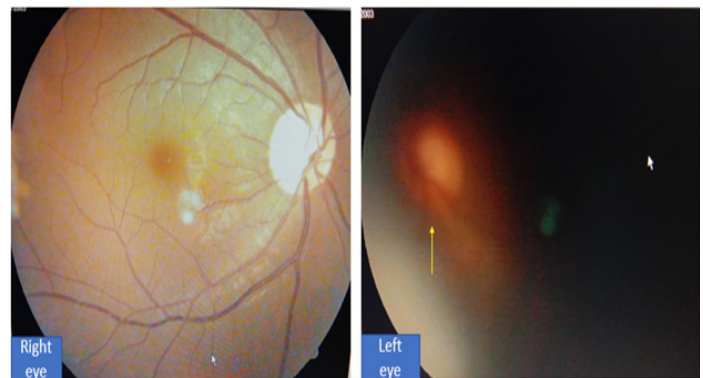

Figure 2. Media clear in right eye with normal fundus. In left eye media is hazy and blurry disc margin (yellow arrow) suggestive of optic disc edema

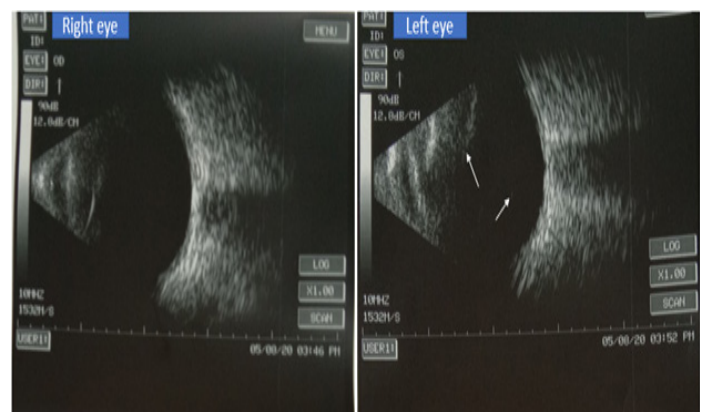


Figure 3. Ultrasound B scan of both eyes. The right eye has echo free vitreous cavity and left eye has dot like hyperreflectivity in vitreous cavity (white arrow)

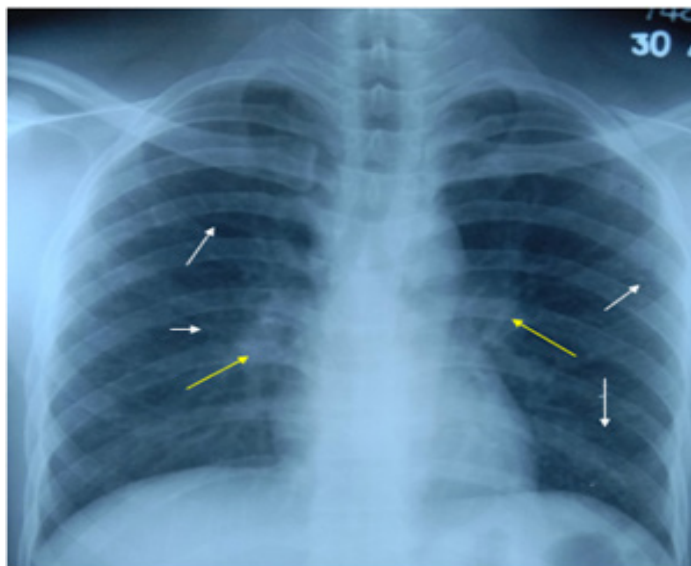


Figure 4. Chest X ray PA view showing radiopaque lesions at hilum (yellow arrow) and multiple small radiopaque lesions (white arrow) in both lung fields

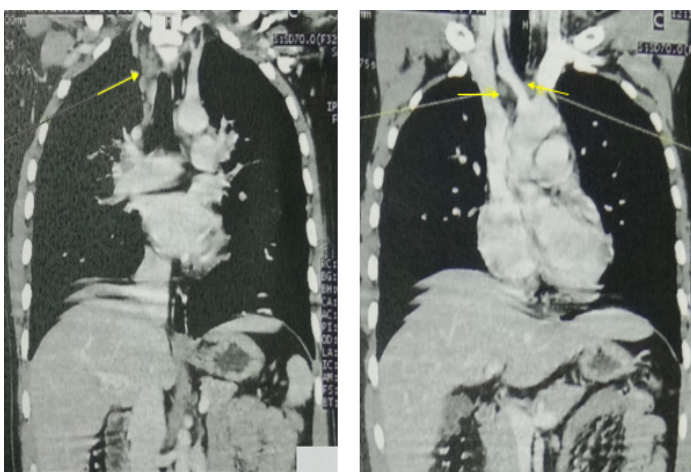


Figure 5. CECT scan of chest showing prominent hilar lymphadenopathy especially in right paratracheal area (yellow arrow)

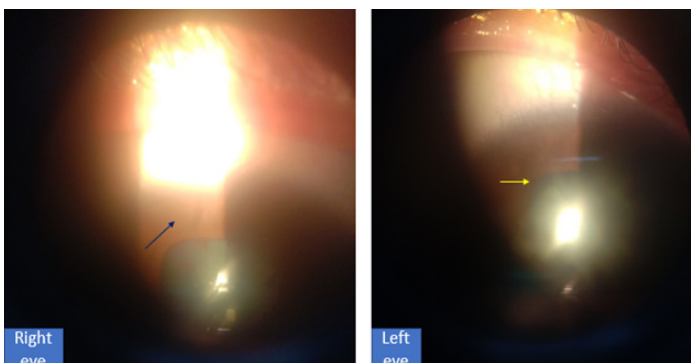


Figure 6. Resolved iris nodule in right eye (blue arrow) and release of posterior synechiae in left eye (yellow arrow)

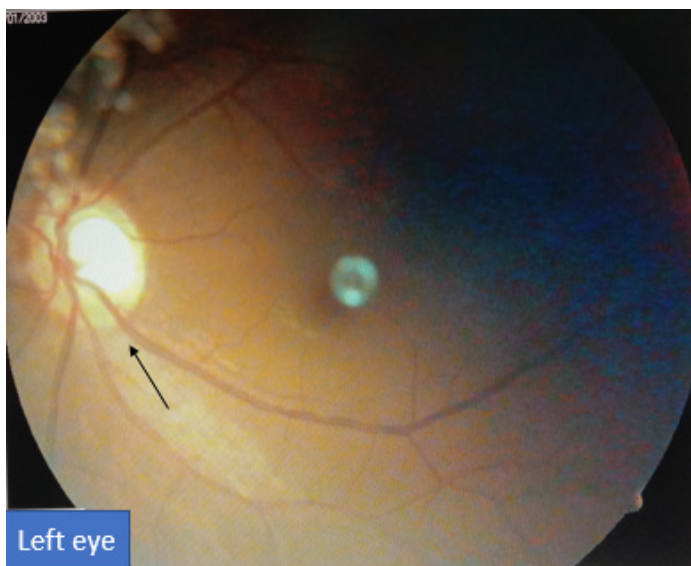


Figure 7. Fundus of left eye showing resolved disc edema (black arrow)

DISCUSSION

The diagnosis of ocular sarcoidosis is quite challenging. It is usually bilateral. As reported in other literatures, the patient had bilateral presentation though it was asymmetrical. It is very essential to rule out other chronic inflammatory condition especially ocular tuberculosis. Therefore a diagnosis of ocular sarcoidosis was made based on the clinical symptoms, signs and investigations¹⁻⁵.

As per the criteria set by revised International Workshop on Ocular Sarcoidosis (IWOS), the patient was diagnosed as presumed ocular sarcoidosis based on compatible clinical features and imaging findings (chest X ray and CECT). The laboratory reports clinching to sarcoidosis were normal ESR and non-reactive mantoux test. With high dose oral steroids, there was marked improvement in visual acuity and resolution of inflammation which further supported the diagnosis.

As mentioned in literatures steroids is the main treatment modality besides immunosuppressive therapy⁶⁻⁸. Accordingly the patient was treated with topical steroids, topical cycloplegics and oral steroid prednisolone for six months. The oral prednisolone was tapered every 2 weekly by 10 mg. He received other supportive medications like proton pump inhibitors and calcium supplements.

N R Acharya et al have mentioned that except bilateral hilar lymphadenopathy no investigative test was highly sensitive for ocular sarcoidosis⁹. This is true in our case as patient had bilateral hilar radiopaque lesion which prompted us to do CECT of chest.

Since patient requires long term steroid therapy they are susceptible to side effects. The most common ocular side effect are raised IOP (glaucoma) and cataract¹⁰⁻¹¹. The patient developed raised IOP after 2 weeks of treatment and was treated effectively with topical antiglaucoma medications.

With high dose of oral prednisolone, clinical signs improved with resolution of iris nodules and inflammation within 2 weeks. In addition the media clarity improved in left eye with resolving vitritis and disc edema. The BCVA improved from 6/18 to 6/9 in left eye at 3 months of treatment and it is maintained in subsequent follow up of 1 year.

CONCLUSIONS

Owing to the complex nature of disease, the treating physician need to have high degree of suspicion of ocular sarcoidosis. A multidisciplinary approach is of paramount important for diagnosis and timely management. It is very important to differentiate from ocular tuberculosis as both can have similar presentations in our part of world where tuberculosis is endemic.

REFERENCES

1. Rybicki BA, Major M, Popovich JJ, Maliarik MJ, Iannuzzi MC. Racial differences in sarcoidosis incidence: a 5 year study in a health maintenance organization. *Am J Epidemiol.* 1997;145(3):234-41. [[PubMed](#) | [DOI](#)]
2. Babu K. Sarcoidosis in tuberculosis-endemic regions: India. *J Ophthalmic Inflamm Infect.* 2013;3(1):53. [[PubMed](#) | [Full Text](#) | [DOI](#)]
3. Rothova A. Ocular involvement in sarcoidosis. *Br J of Ophthalmol.* 2000;84:110-6. [[PubMed](#) | [Full Text](#) | [DOI](#)]
4. Herbot CP, Rao NA, Mochizuki M. International criteria for the diagnosis of ocular sarcoidosis: results of the first international workshop on ocular sarcoidosis (IWOS) ocul. *Immunol Inflamm.* 2009;17(3):160-9. [[PubMed](#) | [DOI](#)]
5. Mochizuki M, Smith JR, Takase H, Kaburaki T, Acharya NR, Rao NA. Revised criteria of international workshop on ocular sarcoidosis (IWOS) for the diagnosis of ocular sarcoidosis. *Br J Ophthalmol.* 2019 Oct;103(10):1418-22. [[PubMed](#) | [DOI](#)]
6. Pasadhika S, Rosenbaum JT. Ocular sarcoidosis. *Clin Chest Med.* 2015 December;36(4):669–683. [[PubMed](#) | [DOI](#)]
7. Yang SJ, Salek S, Rosenbaum JT. Ocular sarcoidosis: new diagnostic modalities and treatment. *Curr Opin Pulm Med.* 2017 Sep;23(5):458–67. [[PubMed](#) | [DOI](#)]
8. Padhy SK, Kumar V. Systemic sarcoidosis presenting as optic nerve head granuloma. *Indian J Ophthalmol.* 2019;67:1714-5. [[Full Text](#) | [DOI](#)]
9. Acharya NR, Browne EN, Rao N, Mochizuki M. Distinguishing features of ocular sarcoidosis in an international cohort of uveitis patients. *Ophthalmology.* 2017;125(1):119-126. [[PubMed](#) | [DOI](#)]
10. A Matsou, Tsaousis KT. Management of chronic ocular sarcoidosis: challenges and solutions. *Clin Ophthalmol.* 2018;12:519–532. [[PubMed](#) | [DOI](#)]
11. Aaberg TM. The role of the ophthalmologist in the management of sarcoidosis. *American Journal of Ophthalmology.* 1987;103(1):99–101. [[Full Text](#) | [DOI](#)]