



<https://doi.org/10.47811/bhj.88>

## Uterus didelphys: a diagnosis in late pregnancy

Nidup Gyeltshen<sup>1</sup>, Namkha Dorji<sup>1</sup>

<sup>1</sup>Department of Obstetrics & Gynaecology, Central Regional Referral Hospital, Gelephu, Bhutan

### ABSTRACT

Uterus didelphys is a rare mullerian duct anomaly (MDA) and often remains undiagnosed till pregnancy or delivery. Obstetric complications can arise especially if undiagnosed in labour with malpresentation or thick inelastic vaginal septum. Some presents with dyspareunia or dysmenorrhea in the presence of a varying degree of longitudinal vaginal septum. Rarely delayed diagnosis can lead to complications that include endometriosis, adhesions, infertility, etc.

**Keywords:** Dysmenorrhea; Dyspareunia; Malpresentation; Mullerian duct anomaly; Uterus didelphys; Vaginal septum.

### INTRODUCTION

Mullerian duct anomalies are congenital defects of the female genital system that arise from abnormal embryological development of the mullerian ducts. These abnormalities can include failure of development, fusion, canalization, or reabsorption, which normally occurs between 6 and 22 weeks in utero. Most sources estimate an incidence of these abnormalities to be from 0.5 to 5.0% in the general population<sup>1,2,3,4</sup>. A review of the prevalence of different types of uterine malformations done by Grimbizis et al. revealed that the septate uterus is most common at 35% followed by bicornuate at 25%, arcuate at 20%, unicornuate at 9.6%, and complete agenesis at 3%. Didelphys uterus found to be the second least common at 8.3% of all MDAs<sup>4</sup>.

Uterus didelphys is suggestive of an embryologic arrest occurring during the 8<sup>th</sup> week of gestation, which ultimately affects the mullerian and metanephric ducts<sup>5</sup>. A didelphys uterus characterized by complete failure of the mullerian ducts to fuse leading to separate uterine cavities and two cervixes. A longitudinal vaginal septum is also present that may range from thin and easily displaced to thick and inelastic. Initial suspicion of the condition followed by the diagnosis usually begins with a routine speculum examination where visualization of anatomical abnormalities warrants further investigation<sup>1,2</sup>. Renal tract anomalies are associated with MDA in up to 30% of cases due to the close embryologic relationship between the paramesonephric and mesonephric ducts. The most common renal tract anomaly associated with MDA is renal agenesis with right sided prevalence<sup>6,7,8</sup>. Very rarely ectopic ureter can be

associated with this syndrome either inserting into the obstructed vaginal cavity or a Gartner's duct cyst on the side of congenitally absent ipsilateral kidney<sup>9</sup>.

The modalities for correct diagnosis frequently used include highly invasive methods such as hysteroscopy, hysterosalpingography, and laparoscopy. Ultrasonography is frequently the first imaging modality in assessing genitourinary pathologies. MRI is an excellent modality for evaluating the frequently complex genitourinary anomalies, given its multiplanar capability, superior tissue characterization and the lack of ionizing radiation.

In this case series, we discuss two cases of undiagnosed didelphys uterus with pregnancy presenting at term.

### CASE REPORTS

#### Case 1

A 23 years old gravida 2, para 0+1, was admitted at the gynaecology ward, CRRH at 41+3 weeks of gestation for induction of labour. Her antenatal period was uneventful. On abdominal examination, the fetus was in cephalic presentation and the head engaged. On vaginal examination, there was thick and elastic longitudinal vaginal septum with two vaginal openings and two cervixes, which confirmed by speculum examination (Figure 1). Taking into consideration the adequacy of the pelvis and elastic vaginal septum, which could be easily pushed laterally, induction of labour was planned. The patient went into labour after induction with tablet misoprostol 25-microgram pervaginally for four doses every 6 hourly. However, an emergency caesarean section was done due to prolonged latent phase with cervical dystocia.

Per operatively, the fetus was noted in the right horn of uterus and a separate smaller non gravid uterus was seen on its left side (Figure 2). Each uterus had a separate tube and ovary. The

#### Corresponding author:

Namkha Dorji

[namji2002@gmail.com](mailto:namji2002@gmail.com)

postoperative period was uneventful and on third post-operative day, patient discharged with advice to follow up after three months with a MRI scan (Figure 3).

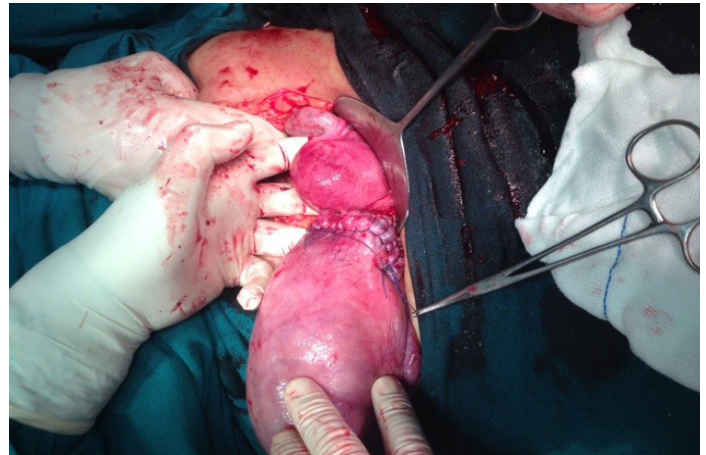
**Case 2**

A 20-year primipara was referred to Central Regional Referral Hospital; Gelephu from a nearby health center for safe delivery at 40 weeks of gestation. She had menarche at 14 years of age with regular menstrual cycle of 28-30 days with heavy blood loss lasting 4-5 days. She also experienced severe dysmenorrhoe and mild superficial dyspareunia.

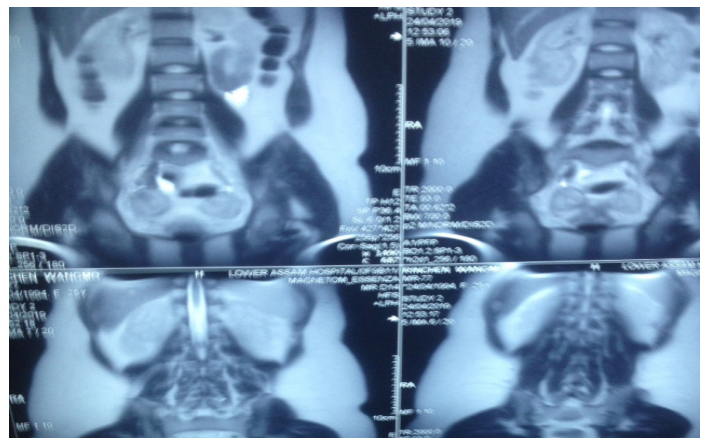
This was a planned and wanted pregnancy. She had ten antenatal clinic visits with an uneventful antenatal period.

On admission, the admitting obstetrician diagnosed oblique lie with non-engaged cephalic presentation. Per vaginal examination revealed complete longitudinal vaginal septum with two cervixes (Figure 4). She was planned for elective caesarean section. However, on the night of admission, the CTG showed base line fetal heart rate of 170 bpm, reduced variability and absent acceleration. She was planned for emergency caesarean section because of fetal distress with uterine didelphys.

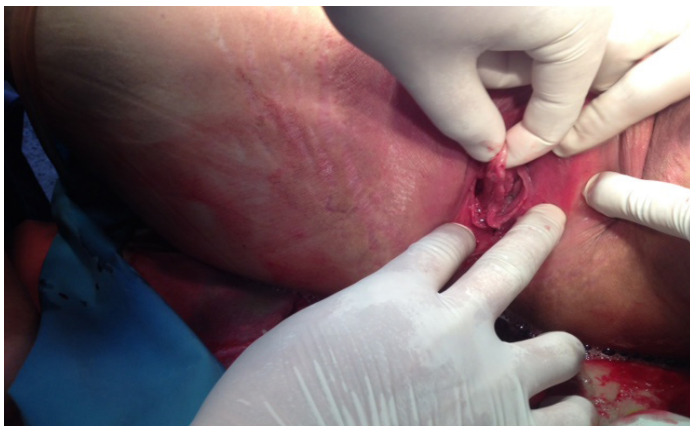Emergency cesarean section under spinal anaesthesia was performed and a live male baby weighing 3.960 kg was delivered at 21:40:35 hours on 4<sup>th</sup> May, 2019 with APGAR score of 7/10 and 9/10 at 1 minutes and 5 minutes of life respectively. There were two uteruses with pregnancy on the left horn (Figure 5). Noted moderate meconium stained amniotic fluid. Both the mother and newborn had an uneventful post-operative recovery and discharged home on 3<sup>rd</sup> postoperative day. Done postpartum ultrasound KUB and X Ray KUB, which did not reveal any abnormality in the kidneys, ureters and bladder.



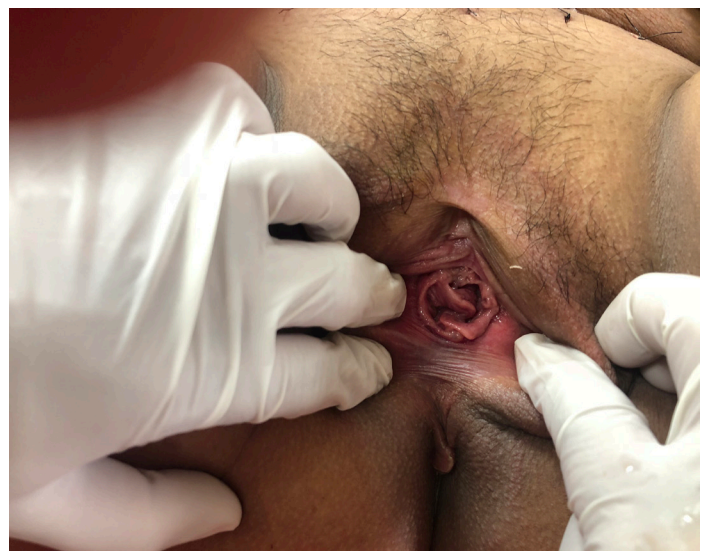**Figure 2. Intra operative image showing small non-gravid uterus on the left side adjacent to lower segment incision on the right uterus**



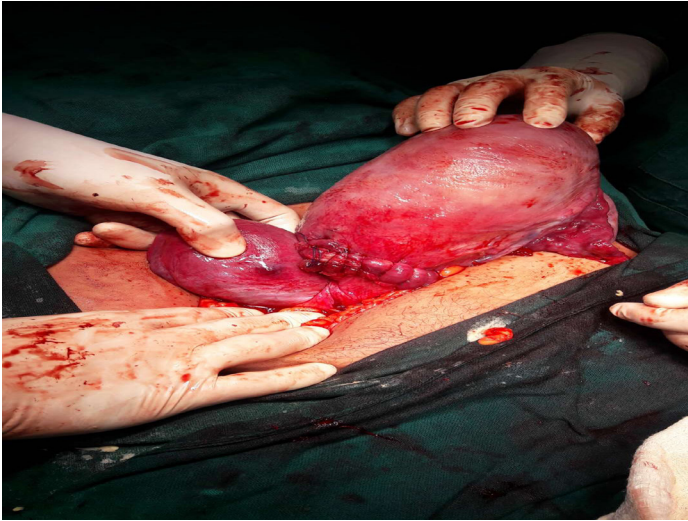
**Figure 3. MRI of case 1**



**Figure 1. Longitudinal vaginal septum with two vaginal opening**



**Figure 4. Longitudinal Vaginal septum**



**Figure 5. Intraoperative finding of fetus in left horn of uterus didelphys**

## DISCUSSION

Generally, it is accepted that having a uterine anomaly is associated with poorer pregnancy outcomes such as increased chances of spontaneous abortion, premature labor, cesarean delivery due to malpresentation, and decreased live births as compared to a normal uterus. However, the degree of these outcomes varies among different types of uterine anomalies. Unicornuate and didelphys uterus have term delivery rates of 45%<sup>1,4</sup>. Most women with a didelphys uterus are asymptomatic, but some present with dyspareunia or dysmenorrhea in the presence of a varying degree of longitudinal vaginal septum. Rarely, genital neoplasms, hematocolpos/hematometocolpos, and renal anomalies are reported in association with didelphys uterus. Despite, some of these complications, there are many cases of women with a didelphys uterus that did not exhibit any reproductive or gestational challenges.

In our case series, the patients were asymptomatic, though one had history of one miscarriage, and the diagnosis was made only at term when they were admitted for delivery. Failure to recognize the condition even in labour can lead to increased morbidity especially in association with mal presentation and/or thick inelastic longitudinal vaginal septum. Confusion can also arise during monitoring in labour with different per vaginal findings regarding cervical dilatation.

Surgical correction of a didelphys uterus (metroplasty) is not usually indicated and the literature on women with didelphys uterus who underwent metroplasty is very limited. With that said, metroplasty would only be considered on a case by case basis after all other ways in which reproductive performance could be improved are exhausted<sup>4,10</sup>. Longitudinal vaginal septum excision is considered if the woman is symptomatic, complaining of dyspareunia or pain from hematometocolpos due to obstruction.

Some septa can be easily displaced to the side to facilitate vaginal birth and others may be thick and inelastic, increasing the risks of vaginal dystocia and thus requiring excision. A didelphys uterus is not an indication for cesarean delivery and thus vaginal delivery should be considered first<sup>11,12</sup>. In our case report that vaginal septum was thick but elastic and could easily be displaced laterally. Vaginal delivery was attempted in one and elective CS was planned in other but emergency caesarean section was done for cervical dystocia and fetal distress respectively.

Cervical incompetence is not usually associated with didelphys uterus and thus cerclage is not routinely used unless there is a history of cervical incompetence or premature dilation is found on exam during early second trimester.

## CONCLUSIONS

Delays in diagnosis have been attributed to lack of understanding of this condition, in some cases, even by radiologists, gynecologists and pediatricians. Delayed diagnosis can lead to complications that include endometriosis, adhesions and infertility. Failure to recognize this condition in pregnancy and labour may cause confusion in monitoring and management especially in centres without gynaecologist. With the case series, we hope to create awareness so that every woman is examined properly, appropriate diagnosis and made timely referral.

## REFERENCES

1. Heinonen PK. Uterus didelphys: a report of 26 cases. *European Journal of Obstetrics & Gynecology and Reproductive Biology*. 1984;17(5):345-50. [\[Full Text\]](#)
2. Heinonen PK. Clinical implications of the didelphic uterus: long-term follow-up of 49 cases. *European Journal of Obstetrics & Gynecology and Reproductive Biology*. 2000;91(2):183-90. [\[Full Text\]](#)
3. Raga F, Bauset C, Remoh Ji, F Bonilla-Musoles, C. Sim' on, Pellicer A. Reproductive impact of congenital: mullerian anomalies. *Human Reproduction*. 1997;12(10): 2277–81. [\[Full Text\]](#)
4. Grimbizis GF, Camus M, Tarlatzis BC, Bontis JN, Devroey P. Clinical implications of uterine malformations and hysteroscopic treatment results. *Human Reproduction Update*. 2001;7(2):161–74. [\[Full Text\]](#)
5. Vercellini P, Daguati R, Somigliana E, Vigano P, Lanzani A, Fedele L. Asymmetric lateral distribution of obstructed hemivagina and renal agenesis in women with uterus didelphys: institutional case series and a systematic literature review. *Fertility sterility*. 2007; 7: 719-20. [\[Full Text | DOI\]](#)

6. Gholoum S, Puligandla PS, Hui T, Su W, Quiros E. Management and outcome of patients with combined vaginal septum, bifid uterus and ipsilateral renal agenesis. *J Pediatr Surg.* 2006; 1(5): 98-92. [[Full Text](#)]
7. Burgis J. Obstructive mullerian anomalies. Case report, diagnosis and management. *Am J Obstet Gynaecol.* 2001; 185: 338-44. [[Full Text](#)]
8. Gruenwald P. Relation of growing mullerian duct to the Wolffian duct and its importance for the genesis of malformation. *Anat Rec.* 1991; 81:1-20.
9. Han B, Herndon CN, Rosen MP, Wang ZJ, Link HD. Uterine didelphys associated with obstructed hemivagina and ipsilateral renal anomaly (OHVIRA) syndrome: Radiology case reports. 2010; 1. [[Full Text](#) | [DOI](#)]
10. Maneschi IF, Maneschi MP, Fuca G, Incandela S. Reproductive performance in women with uterus didelphys. *Acta Europaea Fertilitatis.* 1989;20(3):121–24. [[Full Text](#)]
11. Magudapathi C. Uterus didelphys with longitudinal vaginal septum: normal deliver. Case report. *Journal of Clinical Case Reports.* 2012; 2(13). [[Full Text](#)]
12. Altwerger G, Pritchard AM, Black JD, Sfakianaki AK. Uterine didelphys and vaginal birth after cesarean delivery. *Obs & Gyne.* 2015;125(1):157–59. [[Full Text](#)]